



OPEN ACCESS

ORIGINAL RESEARCH

Initial experience with an extremely soft bare platinum coil, ED coil-10 Extra Soft, for endovascular treatment of cerebral aneurysms

Kei Harada,¹ Jun Morioka²

¹Department of Neurovascular Surgery, Fukuoka Wajiro Hospital Heart and Neuro-Vascular Center, Fukuoka, Japan

²Department of Neurosurgery, Fukuoka Shimizumaki Hospital, Fukuoka, Japan

Correspondence to

Dr Kei Harada, Department of Neurovascular Surgery, Fukuoka Wajiro Hospital Heart and Neuro-Vascular Center, 2-2-75 Wajirogaoka, Higashi-ku, Fukuoka 811-0213, Japan; keihara@f-wajirohp.jp

Received 8 August 2012

Revised 31 October 2012

Accepted 3 November 2012

Published Online First

28 November 2012

ABSTRACT

Background and purpose The ED coil-10 Extra Soft (EDC-10 ES) is an extremely soft coil with excellent operability for embolization of cerebral aneurysms and is frequently used as a 'finishing coil'. The aim of this study was to evaluate the efficacy and safety of this coil.

Methods Clinical data were analyzed retrospectively for 92 consecutive aneurysms for which at least one EDC-10 ES was used. Follow-up angiography at 6 months was available for 69 aneurysms. Initial and follow-up outcomes were evaluated using three-category occlusion grading. Factors that affect the packing density were also investigated.

Results Of the 92 aneurysms, 63 (68.5%) were classified as complete occlusion, 11 (12.0%) as having a neck remnant and 18 (19.6%) with dome filling immediately after the embolization procedure. The mean \pm SD packing density was $29.5 \pm 10.6\%$. Periprocedural complications were observed in three cases (3.3%). At 6 months the rate of completely occluded cases increased to 78.3% (54/69) and those for neck remnant and dome filling decreased to 11.8% (8/69) and 10.1% (7/69), respectively. Recanalization occurred in six aneurysms and one aneurysm was retreated during the follow-up period, giving an overall recurrence rate of 10.0% (7/70). Linear regression analysis showed a significant association of packing density with the percentage EDC-10 ES volume ($p < 0.001$) and with the maximum aneurysm size ($p < 0.001$).

Conclusions Use of the EDC-10 ES permits safe and effective embolization of a cerebral aneurysm and contributes to a reduction in the rate of recanalization.

of coil embolization, including bioactive coils and hydrogel-coated coils. These innovative coil technologies have contributed to a reduction in the recanalization rate, but the problems associated with recanalization have not been completely resolved.^{8,9}

Improvement in the mechanical properties of coils has been achieved by approaches that reduce the stiffness of the platinum element wire and soften the coils to improve handling properties. The EDcoil-10 Extra Soft (EDC-10 ES; Kaneka Medix Corporation, Osaka, Japan) is an extremely soft coil manufactured with an unprecedentedly small diameter of the element coil wire (0.0014 inches). Although the coil is a bare platinum coil, it allows higher packing and contributes to a better outcome through its excellent handling properties due to the extreme softness of the coil. The EDC-10 ES is now commonly used for coil embolization, but the clinical performance of the coil has not been examined in detail. The purpose of this study was to examine the clinical efficacy and safety of the EDC-10 ES for treatment of aneurysms as a representative extremely soft bare coil.

MATERIALS AND METHODS**Patient background and aneurysm characterization**

From April 2008 to December 2010 the EDC-10 ES coil was used in endovascular coil embolization of 92 consecutive cerebral aneurysms in 89 patients in our hospital. These cases were judged to be suitable for embolization after evaluation by neurosurgeons and neurointerventionalists or because the patient refused clipping. The clinical records of these cases were retrospectively analyzed to evaluate the clinical efficacy and safety of the coil.

The background of the patients and aneurysm characterization are summarized in table 1. The patients included 64 women (71.9% of the 89 aneurysms) and had a mean \pm SD age of 60.6 ± 12.2 years (median 62 years; range 31–84 years). Of the 92 treated aneurysms, 34 (37.0%) were unruptured and 58 (63.0%) were ruptured. Of the 58 ruptured cases, the neurological condition was severe (World Federation of Neurosurgical Societies grade 4–5) in 27 (38.6%). The mean \pm SD volume of the 92 aneurysms was 131.3 ± 171.6 mm³ (median 62.8 mm³; range 4.2–867.3 mm³). The maximum aneurysm diameter ranged from 2.0 to 14.0 mm (mean \pm SD 6.5 ± 2.8 mm; median

INTRODUCTION

Two decades have passed since endovascular treatment of cerebral aneurysms with platinum coil embolization was introduced into clinical practice.^{1,2} This treatment has become accepted worldwide as an effective and less invasive alternative to surgical clipping to occlude ruptured and unruptured cerebral aneurysms. The most representative large-scale clinical study, the International Subarachnoid Aneurysm Trial, revealed a significantly lower rate of immediate morbidity and mortality in endovascular coiling than in surgical clipping.³ However, medium- and long-term follow-up of patients treated with coil embolization has shown that some cases undergo compaction of the coil ball and recanalization or regrowth of the treated aneurysm.^{4–7} Various types of coils have been developed to circumvent these disadvantages



Open Access
Scan to access more
free content

To cite: Harada K, Morioka J. *J NeuroIntervent Surg* 2013;5:577–581.

Table 1 Patient background and aneurysm characterization

Number of patients	89
Mean±SD (range) age, years	60.6±12.2 (31–84)
Female	64 (71.9%)
Number of aneurysms	92
Unruptured aneurysms	34 (37.0%)
Ruptured aneurysms	58 (63.0%)
WFNS grade	
1	19 (32.8%)
2	12 (20.7%)
3	0 (0%)
4	11 (19.0%)
5	16 (27.6%)
Total	58 (100%)
Aneurysm location	
Anterior circulation	70 (76.1%)
ICA	46 (50.0%)
ACA	16 (17.3%)
MCA	8 (8.7%)
Posterior circulation	22 (23.9%)
VA	10 (10.9%)
BA	11 (12.0%)
PCA	1 (1.1%)
Aneurysm size	
Mean±SD (range) volume, mm ³	131.3±171.6 (4.2–867.3)
Mean±SD (range) maximum diameter, mm	6.4±2.7 (2.0–14.0)
Mean±SD (range) dome to neck ratio	1.86±0.73 (1.0–4.50)

ACA, anterior cerebral artery; BA, basilar artery; ICA, internal carotid artery; MCA, middle cerebral artery; PCA, posterior cerebral artery; VA, vertebral artery; WFNS, World Federation of Neurosurgical Societies.

6.0 mm). The mean±SD dome size and neck size were 5.8±2.4 mm (median 5.3 mm; range 2.0–12.9 mm) and 3.3±1.4 mm (median 3.0 mm; range 0.9–9.5 mm), respectively. The mean±SD dome to neck ratio of each aneurysm was 1.86±0.73 (median 1.61; range 1.0–4.50). Of the 92 aneurysms, 70 (76.1%) were in the anterior circulation and 22 (23.9%) in the posterior circulation. The aneurysm location is also shown in table 1.

Endovascular treatment

Coil embolization of aneurysms was performed by a single consultant neurosurgeon (KH). Of the 92 embolizations, 41 (44.6%) were performed with a simple technique and 51 with an adjunctive technique, including the balloon-assist technique for 42 (45.7%) and the double catheter technique for 9 (9.8%). Hyperform (ev3, Irvine, California, USA) or Hyperglide (ev3) were used in the balloon-assist technique. In most cases, GDC-18 360, GDC-10 360 (Boston Scientific, Fremont, California, USA), Compass-18, Compass-10 (Terumo, Tokyo, Japan) or Trufill Orbit (Cordis, Miami Lakes, Florida, USA) three-dimensional coils were used as framing coils at initiation of embolization. The EDC-10 ES was mainly used in the middle and later stages of the procedure, and most frequently as a finishing coil in the final stage in all aneurysms.

Angiographic evaluation

A three-dimensional angiogram was recorded immediately after treatment and at follow-up using a biplane system (BRANSIST Safire, Shimadzu, Kyoto, Japan). The size of aneurysms in three planes (height, length and width) was measured on the three-dimensional angiograms with reference markers included in the

view. The maximum aneurysm size was defined as the longest dimension. The aneurysm sac volume was calculated using the following equation:

$$\text{Aneurysmal sac volume} = (4/3) \times \pi \times (\text{length}/2) \times (\text{width}/2) \times (\text{height}/2).$$

The volume of the inserted coil was calculated as follows:

Coil volume = $\pi \times (\text{diameter of coil}/2)^2 \times (\text{length of coil})$. Packing density (%) was calculated by dividing the volume of inserted coils by the volume of the aneurysm×100. The percentage EDC-10 ES volume was calculated by dividing the volume of the inserted EDC-10 ES by the total volume of inserted coils×100.

The neck size indicates the length of the aneurysm orifice plane and the dome size was obtained by measuring the distance between the orifice plane and the fundus of the aneurysm. The degree of aneurysmal occlusion was graded using a modified three-point Raymond score (RS) where RS1 indicates complete obliteration of aneurysm and neck; RS2 indicates small neck remnant without contrast filling of the aneurysm sac; and RS3 indicates contrast filling of the aneurysm sac.¹⁰

Statistical analysis

Linear regression analysis was performed to evaluate the relationships of packing density with dome to neck ratio, maximum aneurysm size, percentage EDC-10 ES volume and aneurysm volume. Statistical analysis was performed using SPSS software V16.0 (SPSS, Chicago, Illinois, USA).

RESULTS

Initial and follow-up angiographic outcomes

Quantitative and angiographic results are summarized in table 2. The mean±SD packing density was 29.5±10.6% (range 15.8–

Table 2 Initial and 6-month follow-up outcomes

Mean±SD (range) packing density, %	29.5±10.6 (15.8–68.4)
Mean±SD (range) ED coil-10 extra soft volume rate, %	40.5±25.1 (4.9–100.0)
Procedural complications	
Total number	3 (3.3%)
Perforation	1 (1.1%)
Ischemia	2 (2.2%)
Transient neurological deficient	1
Permanent neurological deficient	1
Initial angiographic occlusion	
Total number	92
RS1	63 (68.5%)
RS2	11 (12.0%)
RS3	18 (19.6%)
6-month follow-up angiographic occlusion	
Total number	69
RS1	54 (78.3%)
RS2	8 (11.6%)
RS3	7 (10.1%)
Improved	10 (14.5%)
Stable	56 (81.2%)
Worsened	6 (8.7%)
6-month recanalization rate	
Total number	70
Recanalization (worsened+retreatment)	7 (10.0%)

RS, Raymond score.

68.4%) and the mean \pm SD percentage EDC-10 ES volume was 40.5 \pm 25.1% (range 4.9–100.0%). Initial angiographic results showed that the sac and neck were completely occluded in 63 (68.5%) of the 92 aneurysms, which were evaluated as RS1. Complete occlusion was not achieved in the other 29 aneurysms, which were classified as RS2 in 11 cases (12.0%) and RS3 in 18 (19.6%).

Of the 63 aneurysms initially graded as RS1, 47 were stable and evaluated as RS1, 1 had degraded to RS2 and the other 15 had been lost to follow-up at 6 months after treatment. Of the 11 aneurysms initially graded as RS2, 2 had improved to RS1, 5 were stable, 2 had degraded to RS3 and 2 had been lost to follow-up at 6 months. Of the 18 aneurysms initially graded as RS3, 7 had improved to RS1 or RS2, 2 were stable, 3 had worsened within the RS3 grade, 1 had been retreated and 5 had been lost to follow-up at 6 months.

In total, one ruptured aneurysm was retreated due to recanalization and 22 were lost to follow-up during the 6-month follow-up period, included 19 ruptured and 3 unruptured aneurysms. Therefore, 69 aneurysms (38 ruptured and 31 unruptured) were subjected to angiographic evaluation at 6 months after treatment. Compared with the initial results, the angiographic outcome improved in 7 (10.1%) cases, worsened in 6 (8.7%) and remained at the same grade in 56 (81.2%). Thus, 54 (78.3%) of the 69 aneurysms were graded as RS1, 8 (11.6%) as RS2 and 7 (10.1%) as RS3 at 6 months after treatment. Of these 69 aneurysms, the 6 degraded aneurysms were considered to be recanalized. With addition of the one early recanalized aneurysm during the follow-up period, the overall recanalization rate was 7/70 (10.0%).

Clinical and technical complications

Clinical complications were observed in three of the 92 patients (3.3%), including one aneurysmal perforation with no symptoms and two ischemic complications, including one that caused a permanent deficit in the visual field and one transient deficit. There was no technical complication including unraveling of coils during the embolization procedure.

Factors affecting the packing density

Linear regression analysis was conducted to examine parameters with a possible effect on packing density. There was no significant correlation between the dome to neck ratio and packing density (figure 1A; $R=0.12$; 95% CI -4.74 to 1.29 ; $p=0.258$). Aneurysm volume had a weak but significant correlation with packing density (figure 1B; $R=0.38$; 95% CI -0.04 to -0.01 ; $p<0.001$) whereas, interestingly, percentage EDC-10 ES volume

had a stronger significant correlation (figure 1C; $R=0.55$; 95% CI 0.16 to 0.30 ; $p<0.001$).

DISCUSSION

Coil embolization is widely accepted as a safe and effective treatment option for cerebral aneurysms^{3 11} but the high rate of recanalization is a remaining problem. The rate of recanalization of aneurysms embolized with bare platinum coils can be as high as 20–40%.^{10 12–14} Second-generation aneurysm embolization coils, including surface-modified coils, have been developed to reduce this high recanalization rate. The matrix coil was the first surface-modified coil, with the wire strand coated with biodegradable polymer to induce mild inflammation and accelerate intra-aneurysmal clot formation, thus preventing inflow of circulating blood from the parental artery to the aneurysmal sac.^{15 16} However, the initial results with the matrix coil were not satisfactory in terms of reduction of the recanalization rate, which still remained at well over 10%. These disappointing results were attributed to inadequate packing of the aneurysm due to handling difficulties of the coil caused by friction produced by the uneven surface design of the coated polymer.^{8 9} The surface of a subsequent coil, Matrix 2, was therefore refined to reduce friction, and the markedly improved operability permitted attainment of a recanalization rate of less than 10%.¹⁷

Cerecyte is another bioactive coil that includes a strand of biodegradable polymer inside the primary wind of the coil to improve ease of handling. The surface of the coil is as smooth as an ordinary bare platinum coil and coil friction is reduced. In a report of initial experience and early follow-up results with Cerecyte treatment, Butteriss *et al* found a reasonably favorable recanalization rate of 20.6% in cases treated exclusively with Cerecyte coils after a 6-month follow-up period.¹⁸ Linfante *et al* obtained better results with only five cases of recanalization in 45 cases (11.1%) at 12-month follow-up angiography.¹⁹ These results suggest that improved handling properties contribute to reducing recanalization.

The HydroCoil is an innovative surface-modified coil coated with a swelling hydrogel to increase the embolization volume.²⁰ While the coil acquires higher packing density than the same volume of platinum coils by expanding the coil volume after deployment, handling is not optimal mainly because of the stiffness and friction of the coil caused by the hydrogel overlaying the coil surface. Thus, improvement of the recanalization rate with the HydroCoil has not been as good as expected. Gunnarsson *et al* found average recanalization rates of 17.7% for small aneurysms (<10 mm) and 28.6% for large aneurysms (10–25 mm) at a mean follow-up of 16.3 months²¹ while Deshaies *et al* found

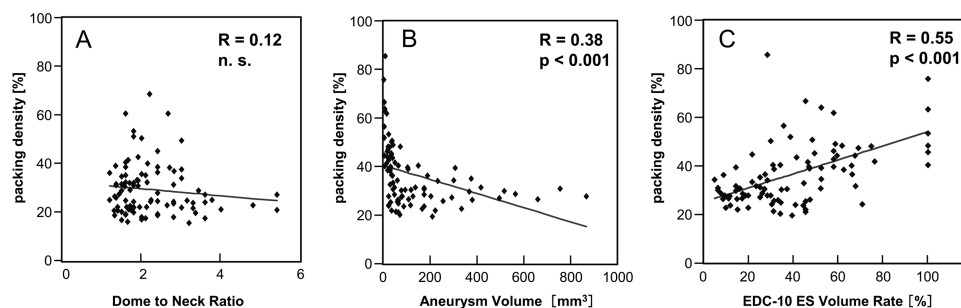


Figure 1 Linear regression analyses between packing density and (A) dome to neck ratio, (B) aneurysm volume and (C) ED coil-10 Extra Soft (EDC-10 ES) volume rate. Dome to neck ratio had no significant correlation with packing density while aneurysm volume and EDC-10 volume rate showed significant correlations with packing density.

a recanalization rate of 15% after 1-year follow up in 67 cases, although a better rate of 6% was obtained in small aneurysms (<15 mm).²² However, a recent report showed an excellent outcome for a novel type of HydroCoil, the HydroSoft coil, in a Korean multicenter study of angiographic follow-up data performed 6 months after coil embolization, with recanalization in only three (2.9%) of 105 aneurysms.²³ Unlike the HydroCoil, the HydroSoft coil is a platinum coil with an inner core of hydrogel. The coil is therefore softer and smoother than the HydroCoil. These properties are likely to improve the operability of the coil and contribute to a reduction in the rate of recanalization. Thus, the findings to date indicate that improved operability is important in reducing recanalization.

The EDC-10 ES is a bare platinum coil with excellent handling properties attributable to the following features. First, the coil is extremely soft due to an unprecedentedly small diameter of the element wire (0.0014 inches) and also because the very flexible pusher wire system has an excellent preventive effect on microcatheter kickback. Second, detachment of the coil is rapid and secure based on the electrodetachable system with a polyvinyl alcohol (PVA) rod at the junction of the platinum coil and delivery wire. By applying high-frequency electric current from the proximal end of the delivery wire, the PVA junction is instantly disrupted by heat generated by electricity conduction and the coil is detached quickly and securely. In addition, the detachment point can be detected by sound in a case in which detection cannot be achieved with angiography. The EDC-10 ES also has the lowest profile of 1.5 mm in diameter and 1 cm in length, which facilitates embolization of small gaps with coil mass. These characteristics of the coil lead to its frequent use in the final stage of aneurysm embolization to allow insertion of more coils and increase the packing density. We experienced many cases in which EDC-10 ES coils smoothly entered an aneurysm in cases in which ordinary coils could not be inserted.

In our treatment series, the EDC-10 ES was used in the final stage of embolization in all cases and the overall percentage EDC-10 ES volume of 40.5% led to an average packing density of 29.5%. Several studies of the relationship between packing density and the stability of embolized aneurysms have shown that packing density is the most important factor affecting the rate of recanalization. Yagi *et al* performed angiographic follow-up of 57 aneurysms embolized solely with GDCs for more than 6 months and showed that aneurysms with a packing density <25% were significantly more frequently recanalized than those with a packing density >25%.²⁴ Sluzewski *et al* also demonstrated that inserting as many coils as possible into an aneurysm is beneficial in terms of avoiding recanalization by showing no recanalization in aneurysms with a packing density $\geq 24\%$ at 6 months follow-up.²⁵ Other reports have also presented critical packing densities related to the incidence of recanalization, varying from approximately 20%–30%.^{26 27} A packing density of almost 30% was obtained in our treatment series, which should be sufficient for inhibition of recanalization based on the earlier studies.

To clarify the beneficial effects of the coil, numerical parameters including the percentage EDC-10 ES volume were examined as potential factors that affected the packing density. In linear regression analysis, a smaller aneurysm volume and a larger percentage EDC-ES volume significantly increased packing density whereas the dome to neck ratio had no significant effect (figure 1). Interestingly, the percentage EDC-10 ES volume showed a higher correlation coefficient ($R=0.55$) than that for aneurysm volume ($R=0.38$). Therefore, use of more EDC-10 ES coils may contribute to a higher packing density.

Regression analysis between packing density and the percentage EDC-10 ES volume also provides a rough indication of the EDC-10 ES volume required for preventing recanalization. Assuming that a 25% packing density is an index for stable embolization, a 17.6% EDC-10 ES volume is required based on the regression equation deduced from the analysis shown in figure 1C. In fact, we used EDC-10 ES coils as 40.5% of the total volume and obtained a packing density of 29.5%. Thus, using more EDC-10 ES coils is likely to contribute to increasing the packing density. Achievement of adequate packing then reduces the recanalization rate.

In this study we examined the clinical records of 92 aneurysms treated with coil embolization in which at least one EDC-10 ES coil was used, with the goal of evaluating the efficacy and safety of this coil. Although the EDC-10 ES is an extremely soft bare platinum coil, the overall results were comparable to those for most studies using second-generation coils. Throughout our treatment series only three (3.3%) periprocedural complications occurred (table 2) and none were due to the properties of the coil. This result shows the safety of the EDC-10 ES. The rate of complete occlusion (RS1) was 68.5% (63/92) at the point of initial treatment which improved to 78.3% (54/69) at 6 months later. Recanalization occurred in only seven of 70 aneurysms (10.0%) in our treatment series, indicating a similar or better recanalization rate than most reported series.

The main limitation of this study is that data were examined from a small number of cases based on a short-term follow-up period. Another limitation is the study design of retrospective observation. Therefore, the results require validation in a multicenter prospective cohort study with a larger number of cases and a longer follow-up period. Within these limitations, we found that the EDC-10 ES coil has excellent handling properties due to the softness of the coil filament and that these beneficial properties led to adequate embolization and a higher packing density. This contributed to a reduced recanalization rate comparable to that of second-generation coils.

CONCLUSION

Embolization of cerebral aneurysms with an extremely soft bare platinum coil (EDC-10 ES) resulted in a favorable packing density and recanalization rate. These results show that improvement of the mechanical properties of embolization coils produces desirable effects on handling properties and contributes to a better outcome.

Acknowledgements The authors thank Hideo Niwa (Kaneka Medix Corporation) for help with statistical analysis.

Contributors KH was a main operator of the endovascular treatment, designed the research and drafted the manuscript. JM was a main assistant of the endovascular treatment and reviewed the manuscript.

Funding None.

Competing interests None.

Patient consent Obtained.

Provenance and peer review Not commissioned; externally peer reviewed.

Open Access This is an Open Access article distributed in accordance with the Creative Commons Attribution Non Commercial (CC BY-NC 3.0) license, which permits others to distribute, remix, adapt, build upon this work non-commercially, and license their derivative works on different terms, provided the original work is properly cited and the use is non-commercial. See: <http://creativecommons.org/licenses/by-nc/3.0/>

REFERENCES

- Guglielmi G, Vinuela F, Sepetka I, *et al*. Electrothrombosis of saccular aneurysms via endovascular approach. Part 1: electrochemical basis, technique, and experimental results. *J Neurosurg* 1991;75:1–7.

- 2 Guglielmi G, Vinuela F, Dion J, *et al*. Electrothrombosis of saccular aneurysms via endovascular approach. Part 2: preliminary clinical experience. *J Neurosurg* 1991;75:8–14.
- 3 Molyneux A, Kerr R, Stratton I, *et al*. International Subarachnoid Aneurysm Trial (ISAT) of neurosurgical clipping versus endovascular coiling in 2143 patients with ruptured intracranial aneurysms: a randomised trial. *Lancet* 2002;360:1267–74.
- 4 Vinuela F, Duckwiler G, Mawad M. Guglielmi detachable coil embolization of acute intracranial aneurysm: perioperative anatomical and clinical outcome in 403 patients. *J Neurosurg* 1997;86:475–82.
- 5 Cognard C, Weill A, Spelle L, *et al*. Long-term angiographic follow-up of 169 intracranial berry aneurysms occluded with detachable coils. *Radiology* 1999;212:348–56.
- 6 Mordasini P, Schroth G, Guzman R, *et al*. Endovascular treatment of posterior circulation cerebral aneurysms by using Guglielmi detachable coils: a 10-year single-center experience with special regard to technical development. *AJNR Am J Neuroradiol* 2005;26:1732–8.
- 7 White PM, Raymond J. Endovascular coiling of cerebral aneurysms using "bioactive" or coated-coil technologies: a systematic review of the literature. *AJNR Am J Neuroradiol* 2009;30:219–26.
- 8 Niimi Y, Song J, Madrid M, *et al*. Endosaccular treatment of intracranial aneurysms using matrix coils: early experience and midterm follow-up. *Stroke* 2006;37:1028–32.
- 9 Fiorella D, Albuquerque FC, McDougall CG. Durability of aneurysm embolization with matrix detachable coils. *Neurosurgery* 2006;58:51–9.
- 10 Raymond J, Guilbert F, Weill A, *et al*. Long-term angiographic recurrences after selective endovascular treatment of aneurysms with detachable coils. *Stroke* 2003;34:1398–403.
- 11 Elijovich L, Higashida RT, Lawton MT, *et al*. Predictors and outcomes of intraprocedural rupture in patients treated for ruptured intracranial aneurysms: the CARAT study. *Stroke* 2008;39:1501–6.
- 12 Murayama Y, Nien YL, Duckwiler G, *et al*. Guglielmi detachable coil embolization of cerebral aneurysms: 11 years' experience. *J Neurosurg* 2003;98:959–66.
- 13 Gonzalez N, Murayama Y, Nien YL, *et al*. Treatment of unruptured aneurysms with GDCs: clinical experience with 247 aneurysms. *AJNR Am J Neuroradiol* 2004;25:577–83.
- 14 Ng P, Khangure MS, Phatourous CC, *et al*. Endovascular treatment of intracranial aneurysms with Guglielmi detachable coils: analysis of midterm angiographic and clinical outcomes. *Stroke* 2002;33:210–17.
- 15 Murayama Y, Vinuela F, Tateshima S, *et al*. Bioabsorbable polymeric material coils for embolization of intracranial aneurysms: a preliminary experimental study. *J Neurosurg* 2001;94:454–63.
- 16 Murayama Y, Vinuela F, Tateshima S, *et al*. Cellular responses of bioabsorbable polymeric material and Guglielmi detachable coil in experimental aneurysms. *Stroke* 2002;33:1120–8.
- 17 Ishii A, Murayama Y, Nien YL, *et al*. Immediate and midterm outcomes of patients with cerebral aneurysms treated with Matrix1 and Matrix2 coils: a comparative analysis based on a single-center experience in 250 consecutive cases. *Neurosurgery* 2008;63:1071–7.
- 18 Butteriss D, Gholkar A, Mitra D, *et al*. Single-center experience of Cerecyte coils in the treatment of intracranial aneurysms: initial experience and early follow-up results. *AJNR Am J Neuroradiol* 2008;29:53–6.
- 19 Linfante I, DeLeo MJ 3rd, Gounis MJ, *et al*. Cerecyte versus platinum coils in the treatment of intracranial aneurysms: packing attenuation and clinical and angiographic midterm results. *AJNR Am J Neuroradiol* 2009;30:1496–501.
- 20 Kallmes DF, Fujiwara NH. New expandable hydrogel-platinum coil hybrid device for aneurysm embolization. *AJNR Am J Neuroradiol* 2002;23:1580–8.
- 21 Gunnarsson T, Tong FC, Klurfan P, *et al*. Angiographic and clinical outcomes in 200 consecutive patients with cerebral aneurysm treated with hydrogel-coated coils. *AJNR Am J Neuroradiol* 2009;30:1657–64.
- 22 Deshaies EM, Adamo MA, Boulos AS. A prospective single-center analysis of the safety and efficacy of the hydrocoil embolization system for the treatment of intracranial aneurysms. *J Neurosurg* 2007;106:226–33.
- 23 Park JH, Kang HS, Han MH, *et al*. Embolization of intracranial aneurysms with HydroSoft coils: results of the Korean multicenter study. *AJNR Am J Neuroradiol* 2011;32:1756–61.
- 24 Yagi K, Satoh K, Satomi J, *et al*. Evaluation of aneurysm stability after endovascular embolization with Guglielmi detachable coils: correlation between long-term stability and volume embolization ratio. *Neurol Med Chir (Tokyo)* 2005;45:561–5.
- 25 Sluzewski M, van Rooij WJ, Slob MJ, *et al*. Relation between aneurysm volume, packing, and compaction in 145 cerebral aneurysms treated with coils. *Radiology* 2004;231:653–8.
- 26 Kawanabe Y, Sadato A, Taki W, *et al*. Endovascular occlusion of intracranial aneurysms with Guglielmi detachable coils: correlation between coil packing density and coil compaction. *Acta Neurochir (Wien)* 2001;143:451–5.
- 27 Tamatani S, Ito Y, Abe H, *et al*. Evaluation of the stability of aneurysms after embolization using detachable coils: correlation between stability of aneurysms and embolized volume of aneurysms. *AJNR Am J Neuroradiol* 2002;23:762–7.



Initial experience with an extremely soft bare platinum coil, ED coil-10 Extra Soft, for endovascular treatment of cerebral aneurysms

Kei Harada and Jun Morioka

J NeuroIntervent Surg 2013 5: 577-581 originally published online November 28, 2012
doi: 10.1136/neurintsurg-2012-010498

Updated information and services can be found at:
<http://jnis.bmj.com/content/5/6/577>

These include:

References

This article cites 27 articles, 14 of which you can access for free at:
<http://jnis.bmj.com/content/5/6/577#BIBL>

Open Access

This is an Open Access article distributed in accordance with the Creative Commons Attribution Non Commercial (CC BY-NC 3.0) license, which permits others to distribute, remix, adapt, build upon this work non-commercially, and license their derivative works on different terms, provided the original work is properly cited and the use is non-commercial. See: <http://creativecommons.org/licenses/by-nc/3.0/>

Email alerting service

Receive free email alerts when new articles cite this article. Sign up in the box at the top right corner of the online article.

Topic Collections

Articles on similar topics can be found in the following collections

[New devices](#) (169)
[Open access](#) (69)

Notes

To request permissions go to:
<http://group.bmj.com/group/rights-licensing/permissions>

To order reprints go to:
<http://journals.bmj.com/cgi/reprintform>

To subscribe to BMJ go to:
<http://group.bmj.com/subscribe/>